ClinicalKey
ELSEVIER

FULL TEXT ARTICLE

Bariatric Surgery: A Review of the Available Procedures and Complications for the Emergency Physician

Stefanie R. Ellison MD, FACEP and Scott D. Ellison MD, FACS

Journal of Emergency Medicine, 2008-01-01, Volume 34, Issue 1, Pages 21-32, Copyright © 2008 Elsevier Inc.

Abstract

Morbid obesity is a serious and widespread disease that has considerable morbidity and mortality. Bariatric surgery has become widely available in both community and academic centers as a weight loss option for the morbidly obese. Although the procedure is offered to patient screening process, it is highly invasive and is performed in patients with significant pre-existing comorbidities from obesity. Know postoperative complications and their management is important as it will affect Emergency Departments nationwide. A basic unde available procedures, the anatomical changes of each procedure, and the common complications for each is important to the emer who will need to evaluate and manage the postbariatric surgery patient.

Want to stay on top latest issues?

By subscribing to New Alerts, you will receiv email notification wher new issue of this jour released including the t contents. You need a p account to use this fe

Login Regi

Introduction

It is estimated that 50% of Americans are overweight and that 1 in 5 are obese (1 2). The prevalence of obesity has tripled in the la It is estimated that 300,000 deaths per year are related to obesity and 100 billion dollars are spent on obesity-related health care costs (3). Traditional treatment of obesity with weight loss, exercise regimens, diet, and drug therapies have shown limited long-term weight loss. However, bariatric surgical procedures are associated with significant weight loss success, sustained long-term weight loss, and reversal of obesity comorbidities. Bariatric surgery for the treatment of morbid obesity is increasing in academic and community hospitals nationwide. The American Society for Bariatric Surgery has estimated that in 2001, 2002, and 2003 there were 47,000, 63,000, and 98,000 bariatric surgeries, respectively, performed in the United States (4). With this increasing rate of surgery for morbid obesity, one can expect to see more patients in the Emergency Department (ED) in the postoperative period. It is important that emergency physicians be familiar with the various bariatric procedures, the potential short- and long-term complications of each, and the diagnostic tests and ED care of these patients.

The following is a review of current surgical and bariatric literature on the available bariatric surgeries. Each procedure will be discussed in detail regarding anatomy and effect on weight loss. The postoperative complications will be reviewed to improve the emergency physician's working knowledge of patient presentation and for diagnosis and treatment after bariatric surgery.

Background

Review of Morbid Obesity

Obesity is defined by body mass index (BMI) and is calculated using the following equation:

$$\text{BMI} = \left[\text{weight}(\text{kg})/\text{height}(\text{meters})^2\right]$$

The lowest mortality for patients is seen when their BMI is maintained at 20–25 kg/m^2. The World Health Organization has divided obesity into three classes: Class I is 30–34.9 kg/m^2, Class II is 35–39.9 kg/m^2, and Class III is ≥40 kg/m^2. Class I has a moderate risk for obesity-related illness, Class II has a severe risk, and Class III has a very severe risk for obesity-related illness (5). There are an estimated 1.5 million Americans that have BMI >40 kg/m^2.

Patient Inclusion Criteria for Bariatric Procedures

The National Institutes of Health Consensus Development Conference Statement of March 1991 established the inclusion criteria for bariatric surgery as (6 7):

- Patient must be motivated, well informed with acceptable operative risks between the patient and surgeon
- BMI > 40
- Some cases of BMI 35–40 are acceptable if high-risk comorbid conditions such as cardiopulmonary, severe obstructive sleep apnea, Pickwickian syndrome, obesity-related cardiomyopathy, or severe diabetes mellitus, joint disease, social effects on employment, family function, or ambulation.

The following is a review of available bariatric surgical procedures in the United States. The discussion includes anatomical changes for restriction and malabsorption as well as weight loss success rates.

Roux-en-Y gastric bypass (RYGBP)

This procedure was established in 1977 and is currently the standard by which all bariatric surgery is compared today (7 8). RYGBP consists of construction of a proximal gastric pouch with a Y-shaped outlet of jejunum of varying lengths and can be performed with either the open or laparoscopic approach (Figure 1 (fig1) A and 1 (fig1) B). The stomach is partitioned by a staple line bypassing the lower stomach. The stomach is usually divided at the partition, which decreases staple line disruption and decreases the development of marginal ulcer, an ulcer that develops on the jejunal side of the anastamosis. This is both a restrictive and malabsorptive procedure, with the degree of malabsorption determined by the length of the jejunum attached at the stomach outlet (9 10). Success rates for weight loss in open RYGBP range from 50–62% of excess weight lost over a 5-year period (10 11 12 13 14). Two prospective randomized studies that compare open RYGBP to the laparoscopic method report excess weight loss for the laparoscopic method in the 65–81% range at 1 year (11 13). There aren't long-term studies for the laparoscopic method and it is likely that the long-term weight loss will be comparable to that of open RYGBP (10 15).

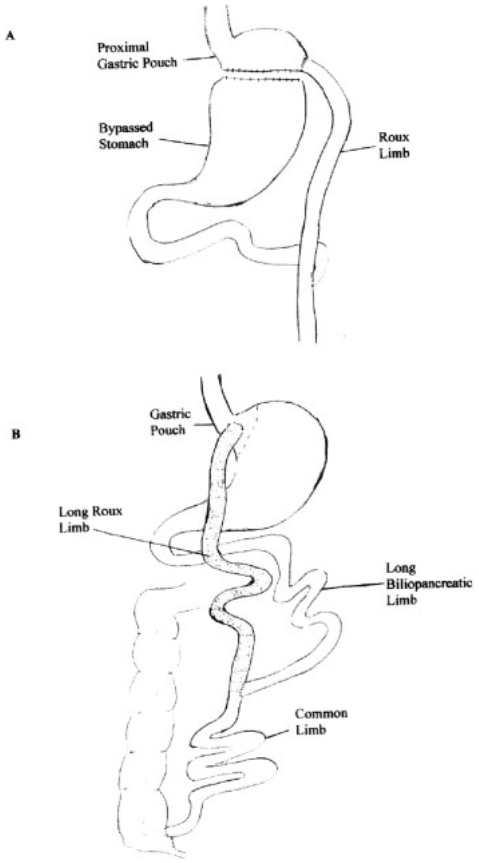

Figure 1

(A) Roux-en-Y Gastric Bypass with divided stomach. (B) Long-limb Roux-en-Y gastric bypass: the shaded long Roux limb is the alimentary limb. The common limb is the major digestive limb.

The measured benefit of the RYGBP is not just weight reduction but also a decrease in the comorbidities of morbid obesity. Reversal of medical problems such as type II diabetes mellitis, hypertension, hyperlipidemia, arthritis of large weight-bearing joints, gastroesophageal reflux disease (GERD), esophagitis, obstructive sleep apnea syndrome, and a decrease in cardiac risk by 50% is seen in patients with weight loss from RYGBP (8 10). One distinct advantage of RYGBP over the vertical banded gastroplasty (VBG) procedure is a decrease in 95% of the acid-producing portion of stomach, having a greater impact on the patient with severe GERD (15). Also, there is a more significant reduction in risk for coronary artery disease/adverse coronary events of RYGBP over the VBG procedure (16).

Vertical banded gastroplasty (VBG)

This procedure was established in the 1980s to simplify the gastric resection of RYGBP (9). VBG consists of construction of a small pouch of the upper stomach with a restricted outlet along the lesser curvature (Figure 2 (fig2)). The stomach is partitioned with staples and a window is created in the stomach to create the outlet. The outlet may be reinforced externally with a mesh band or a Silastic ring to prevent dilatation or disruption of the outlet (9 10). This is strictly a restrictive procedure, and patients have been able to out-eat their weight loss by frequent eating and with junk food. The excess weight loss is reported as 45–53% up to 10 years after surgery, and the super-obese had the most disappointing sustained weight loss at 10 years (17 18). Weight loss results are less than that of RYGBP but are still considered satisfactory, and the procedure is still performed in some bariatric centers.

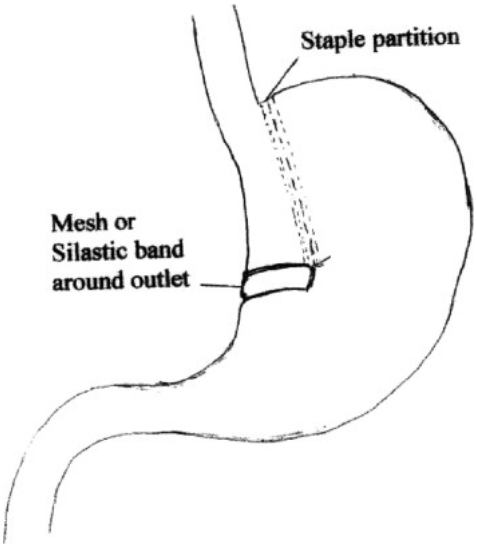

Figure 2
Vertical banded gastroplasty.

Biliary-pancreatic diversion with or without duodenal switch (BPD, BPD-DS)

Scopinaro in Genoa, Italy developed this procedure to be both restrictive and malabsorptive (9). A distal gastrectomy is performed and a small bowel limb 250 cm from the ileocecal valve is anastomosed to the stomach remnant. The biliopancreatic limb is then anastomosed to the side of the distal limb 50 cm from the ileocecal valve. This limb is around 200 cm in length and is considered the alimentary limb. The 50 cm that remains is where food is deposited and digested and is referred to as the common limb (10). The weight loss is both a product of restriction of the stomach and the diversion of food, bile, and pancreatic digestive juices into the distal ileum (Figure 3 (fig3) A). Duodenal switch is a variation in the BPD procedure that creates a vertical gastrectomy along the greater curvature but leaves the pylorus and proximal duodenum intact to anastomose to the small bowel 250 cm from the ileocecal valve (Figure 3 (fig3) B). Prophylactic cholecystectomy is sometimes performed at the time of BPD to prevent the formation of gallstones (9 10). BPD is well established in Europe but there have been increasing procedures of this type being performed in the United States. Success rates are 61–80% of excess weight lost in a 5- to 12-year period and are the highest reported of all bariatric procedures (19 20 21).

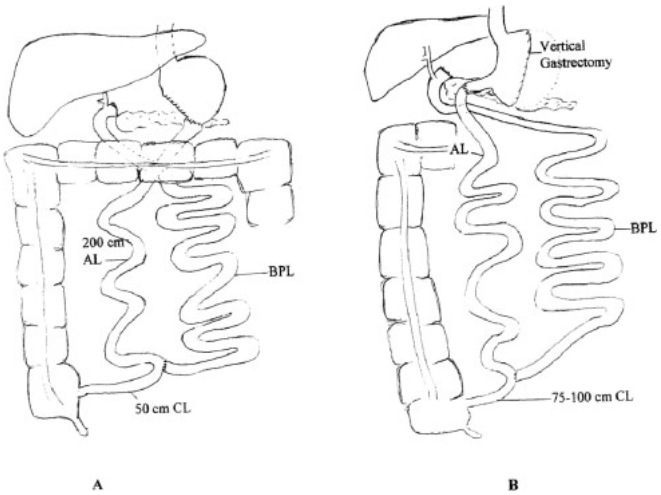

Figure 3
(A) Biliopancreatic diversion (BPD). The biliopancreatic limb (BPL) is anastomosed to the side of the distal limb 50 cm from the ileocecal valve, creating the common limb (CL). The 200-cm proximal limb is the alimentary limb (AL). (B) Biliopancreatic diversion with duodenal switch (BPD-DS). A vertical gastrectomy is performed, leaving the greater curvature of the stomach. The alimentary limb is anastomosed to the divided proximal duodenum. The biliopancreatic limb is anastomosed 75–100 cm proximal to the ileocecal valve, creating the distal common limb (CL).

Laparoscopic adjustable band gastroplasty (LAGB)

LAGB is now becoming more popular as a less-invasive option for bariatric surgery. An adjustable hollow silastic band is placed around the proximal stomach, creating a restrictive pouch (Figure 4 (fig4)). A tube and port are extended from the band to the anterior rectus sheath. The band is secured with gastrogastric sutures to prevent slippage. The port can be accessed through the skin to adjust the band size based on weight loss results. The procedure has short operating times and is adjustable and reversible. The success rates range from 52–68% of excess weight lost over a 10-year period (22 23 24 25 26).

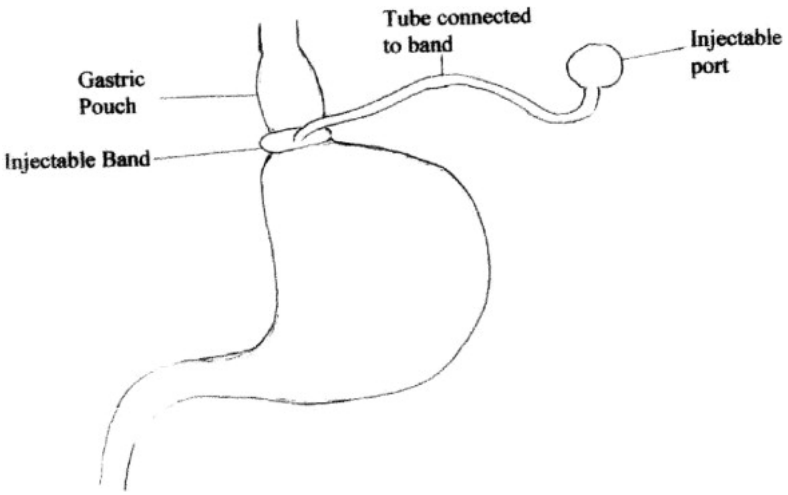

Figure 4

Laparoscopic adjustable band gastroplasty (LAGB). The port under the skin communicates with the band to inject or withdraw saline to adjust the restriction by the band.

Approach to the Postoperative Bariatric Patient

The initial approach to the patient should focus on stabilization of airway, breathing, and circulation. The patient's airway status should be addressed immediately. If the patient is in severe respiratory distress, endotracheal intubation should be considered. Breathing should then be evaluated and stabilized accordingly. Respiratory rate may be a clue to the patient's acid-base status, for example, tachypnea may be a sign of metabolic acidosis in addition to primary pulmonary causes. Bariatric patients often have pulmonary and cardiac comorbidities and this should prompt the emergency physician to examine for signs of congestive heart failure, postoperative pneumonia, postoperative myocardial infarction, exacerbation of pulmonary problems, and pulmonary embolus. Circulation also should be assessed with close attention to the patient's mental status, blood pressure, and heart rate. Postoperative bariatric patients are at risk for dehydration and infection, and the emergency physician should examine closely for evidence of shock. In particular, tachycardia may be a sign of dehydration, sepsis secondary to a postoperative leak, pulmonary embolus, or acute myocardial infarction.

Physical examination of the patient should focus on the clinical signs of dehydration, obstruction, gastrointestinal bleeding, or the appearance of toxicity. Intravenous (IV) access should be obtained and laboratory workup should include complete blood cell count, basic metabolic profile, liver function tests, arterial blood gas, urinalysis, and stool for hemoccult blood. Plain radiographs can be helpful in diagnosing obstruction and ileus. Computed tomography (CT) scan may be necessary to aid diagnosis when plain radiographs are non-diagnostic. After the patient has been stabilized, treatment should include i.v. hydration, control of nausea and vomiting with antiemetics, and pain control. If the patient appears septic, broad-spectrum i.v. antibiotics should be administered immediately.

The most common complaint after bariatric procedures is nausea and vomiting. Vomiting after surgery should not be considered a normal postoperative symptom and should prompt a workup of serious complications. Patients commonly present to the ED complaining of nausea, vomiting, fatigue, diarrhea, food intolerance, crampy abdominal pain, cold intolerance, constipation, or frequent stools at any time during the postoperative period. Evaluation should include a careful history focusing on food intake, adherence to diet restrictions, onset of vomiting, diarrhea, symptoms of dehydration, abdominal pain, hematemesis, or melena.

Complication Rates and Occurrence by Procedure

With the variety of bariatric procedures performed there are complications more specific to each individual procedure. The following is a discussion of complications, relative time of presentation, signs and symptoms, diagnostic testing, and treatment of the postsurgical complications unique to each bariatric procedure.

Early Complications of Open Roux-en-Y Gastric Bypass (RYGBP)

Open RYGBP has a reported mortality of 0.2% in the acute period after the gastric bypass (3 8 9 13). The most common obesity-related cause of mortality is pulmonary embolus followed by other obesity-related pulmonary problems, and the most common surgery-related cause of mortality is anastomotic leak (27). Early postoperative complications include wound infections, wound dehiscence, leaks from the staple/suture anastamosis line, acute gastrointestinal obstruction, stomal stenosis, stomal/marginal ulcers, acute upper gastrointestinal bleeding, and dumping syndrome. Thromboembolic complications including pulmonary embolus and deep venous thrombosis occur in up to 10% of bariatric procedure patients (2 7).

Staple line or anastomotic leak

The frequency of anastomotic leaks is 0.5–5% in the studies reviewed (28 29). Patients most often present in the first week postoperatively but can present up to 1 month after surgery. Anastomotic leak is the most common cause of operative mortality and the most serious complication related to the surgical procedure itself (30). Leaks may occur at the gastrojejunostomy, the gastric remnant, or the gastric pouch (31). Symptoms may be

subtle and limited to tachycardia, dyspnea, restlessness, or mental status changes. The abdominal examination is of limited value and the patient often shows no peritoneal signs. One should suspect a gastrointestinal leak in patients with unexplained sepsis (30). Diagnostic testing should include an upper gastrointestinal (UGI) study with gastrograffin or abdominal CT scan, as both are sensitive in diagnosing the anastomotic leak. Treatment should initially address airway, breathing, and circulation, especially in the patient suspected of sepsis. Oxygen, continuous cardiac monitoring, and intravenous access should be obtained. Fluid resuscitation and broad-spectrum antibiotics also should be initiated. Emergent surgical consultation and exploration is indicated in these patients.

Acute gastrointestinal (GI) obstruction

Acute GI obstruction is usually the result of gastric remnant distention in RYGBP. Symptoms include bloating or hiccups, nausea, vomiting, and abdominal pain. The diagnosis can be made when abdominal X-ray studies reveal massive distention with an air fluid level in the gastric pouch. Treatment includes nasogastric tube insertion and decompression, which can be accomplished in the ED. Other acute causes of gastrointestinal obstruction are internal hernias, adhesions, and intussusception of the Y limb in RYGBP. The restrictive pouch can cause an obstruction secondary to postoperative edema or if the surgical stoma was too small when constructed.

Stomal stenosis

Stomal stenosis is a common complication of RYGBP and occurs in between 1.6% and 20% of open RYGBP patients (28 29 30 31). Stenosis usually presents in the first 6 months after surgery. Symptoms include postprandial epigastric pain and vomiting of undigested solids and may progress to vomiting of liquids. Diagnosis by endoscopy is more sensitive than by a UGI contrast study. Endoscopy can also be therapeutic with dilatations of the stoma (31). Operative revision for stomal stenosis is necessary in a reported 12–50% (31 32).

Stomal ulcers

Stomal ulcers, or marginal ulcers, are less common than stomal stenosis but occur in up to 8% of RYGBP patients and usually present within 2–4 months after surgery (28 29 30 31). Etiology is local ischemia, staple line dehiscence, increased gastric acid production, non-steroidal anti-inflammatory drug use, or tension on the pouch (33). The patient presents with symptoms of epigastric or retrosternal pain, dyspepsia, nausea and vomiting, or an upper gastrointestinal bleed. The diagnostic procedure of choice is endoscopy. Emergent endoscopy should be performed if the patient has gastrointestinal bleeding and shock. Outpatient treatment of the stable patient includes a proton pump inhibitor (PPI) or sucralfate. The patient with gastrointestinal bleeding requiring admission should be resuscitated appropriately and treated with transfusion when necessary, an intravenous PPI, and endoscopy (see upper gastrointestinal bleeding discussion below).

Upper gastrointestinal bleeding (UGIB)

Upper gastrointestinal bleeding is an uncommon but potentially life-threatening complication of any of the bariatric procedures. Early UGIB is most often from the gastrojejunal anastamosis, gastric remnant, or jejunojejunal anastamosis in RYGBP. Signs and symptoms include melena, hematochezia, hematemesis, or hypotension. In the elderly it may present as confusion or altered mental status. Emergent endoscopy is indicated for both diagnosis and treatment. Resuscitation includes aggressive management of airway, breathing, and circulation (ABCs), fluid resuscitation and blood transfusion. Late UGIB can be from a stomal ulcer, a gastric or duodenal ulcer, or from the gastric pouch (34). The ulcer and bleeding can be identified by a bleeding scan or angiography. Endoscopy is helpful only in diagnosing gastric pouch bleeding but not bleeding from the other sites. The ED treatment should include management of ABCs, fluid resuscitation, and an intravenous PPI. Intravenous octreotide should be considered as there is evidence of benefit in non-variceal bleeding of other causes (30).

Dumping syndrome

Dumping syndrome usually occurs in the immediate postoperative period and for up to 12–18 months after the surgery. Non-compliance with the patient's diet is a common and frequent preventable cause. The dumping is caused by the small gastric pouch leading to rapid emptying of gastric contents into the small bowel. Carbohydrate foods, especially those high in sugar, create the worst symptoms and increased transit leading to symptoms (30). Symptoms include diarrhea, abdominal cramps, and nausea and vomiting (9 30). Systemic symptoms include hypotension, tachycardia, lightheadedness, flushing, and syncope. ED treatment is to correct any hypotension or tachycardia, and treat vomiting and electrolyte imbalances. In mild cases the emergency physician should educate the patient to eat small, frequent meals, avoid sugar, consume food slowly with each meal, chew thoroughly, and increase fluid intake between meals.

Iatrogenic splenectomy

Is is reported that during open RYGBP, around 0.41% of patients have an iatrogenic splenectomy as a result of incidental capsule injury and bleeding (28 29 31). Even if these injuries are not recognized intraoperatively, more than likely they will be addressed while the patient is recovering. Although emergency physicians will not need to diagnose a splenic injury, they should investigate the patient's operative history and be cognizant of the potential for serious infection by encapsulated bacterial organisms for that bariatric patient's lifetime.

Stomal obstruction

Stomal obstruction may occur when the stoma is obstructed or narrowed by a food bezoar or by food impaction of poorly chewed food. The most common presenting symptoms are nausea and vomiting, or patients may have difficulty tolerating fluids, including their own secretions. Emergent endoscopy is indicated for both diagnosis and treatment if stomal obstruction is suspected (32 33). If the obstruction is determined to be at the jejunojejunal anastomosis, surgical revision will be required.

Gastroesophageal reflux

Gastroesophageal reflux may be due to pouch overfilling, intraoperative vagal nerve injury, or stomal stricture causing delayed gastric emptying. Symptoms are the same as in the non-bariatric surgery patients but may include more nausea and vomiting. Acid suppression therapy and patient education on how to avoid overeating, to chew food properly, and to eat small frequent meals are the mainstays of treatment.

Cholelithiasis/cholecystitis

It is common to develop cholesterol stones from any of the bariatric procedures described due to rapid weight loss, from bile stasis and bile sludging. There is a patient incidence of up to 36% within 6 months (34). Fifty percent of patients develop symptoms consistent with gallstones, including abdominal pain after eating fatty foods, bloating, and vomiting. Abdominal examination may be remarkable for right upper quadrant tenderness, a palpable gallbladder, or a positive Murphy's sign in cholecystitis. The patient with cholecystitis may have fever, chills, and tachycardia. Diagnosis can be made with ultrasound for cholelithiasis, bile sludging, and cholecystitis. Treatment is cholecystectomy and may be done in the outpatient setting unless the patient has signs or symptoms of cholecystitis. It is important to know the institution's practice on selective prophylactic cholecystectomy during bariatric surgery in narrowing the differential diagnosis of abdominal pain.

Late Complications of Open RYGBP

Vitamin and mineral deficiencies

Vitamin and mineral deficiencies are due to the malabsorptive component of the Roux-en-Y Gastric Bypass (RYGBP). The small pouch can make adequate consumption of nutrients, protein, calories and fluids difficult, as can postoperative symptoms. The cause of vitamin and mineral deficiencies is the diversion of food from the stomach and duodenum leading specifically to malabsorption of iron, vitamin B12, folate and, to a lesser extent, fat-soluble vitamins; calcium, potassium, magnesium, and thiamine. These last vitamins are more deficient in long-limb RYGBP. The signs and symptoms of iron deficiency are mainly from the subsequent iron-deficiency anemia and include weakness, palpitations, and exertional dyspnea. Glossitis with a reddened, swollen, and tender tongue and angular stomatitis consisting of erosion, tenderness, and swelling at the corners of the mouth may occur. Menorrhagia may occur in women and koilonychias, or spoon-shaped nails, may be seen. Pica or cravings for starch, ice, and clay also may be reported (35).

Wenicke-Korsokoff's encephalopathy (WKE)

Thiamine absorption occurs in the proximal small bowel and is disrupted in RYGBP. Daily intake is required to prevent complications of this vitamin deficiency or the patient may develop Wenicke-Korsokoff's encephalopathy (WKE). Signs and symptoms of WKE include nystagmus, ophthalmoplegia, ataxia, altered mental status, confusion, and coma. The oculomotor signs are the most prominent and usually include an abducens palsy with symptoms of horizontal diplopia, strabismus, and nystagmus (36). Confusion and altered mental status follow the ophthalmoplegia and ataxia. The heralding sign may be severe nausea and vomiting. The ED treatment is thiamine 50 mg intramuscular or 100 mg intravenous to avoid loss of mental competency and death. Any patient suspected of WKE should be admitted to monitor for response to treatment and for neurological consultation.

Folate deficiency also occurs and may present as megaloblastic anemia. Usually a stress such as anesthesia with nitrous oxide or administration of trimethoprim will trigger the anemia. Laboratory testing reveals an immune cytopenia with thrombocytopenia or leukopenia without anemia and macrocytosis with a mean corpuscular volume >100 fL (37).

Special issues

Quality-of-life issues include an initial euphoria early in the postoperative period; there is, however, significant late postoperative depression. Some morbidly obese patients have pre-existing depression as a cause for their poor eating habits and this depression is not likely to be improved by the weight-reducing surgery. These patients are at risk for significant depression and may present to the ED with suicidal ideation as well as somatization of depression. In the patient with a negative workup for the complications of bariatric surgery, it is important to inquire about the symptoms of depression.

Complications of Laparoscopic RYGBP

Although the bariatric procedure is the same, the laparoscopic approach has a different type and frequency of postoperative complications when compared to open RYGBP (Table 1 (tbl1)). Certain complications increase with the laparoscopic method, presumably due to the learning curve, whereas other complications decrease due to the less invasive method. Laparoscopy offers a shorter hospital length of stay, earlier return to work, decreased postoperative pain, and a shorter period of recuperation. Laparoscopic RYGBP has lower postoperative wound morbidity with a lower frequency of wound infection and incisional hernias. However, laparoscopic RYGBP also results in a higher frequency of early and late bowel obstruction, GI hemorrhage, and stomal stenosis postoperatively (31). As with the open procedure, there is still the potential for anastomotic leaks, stomal obstruction, and stomal ulcers. These complications are discussed with relation to their frequency compared to that of the open RYGBP, and the reader should refer to that section for the details of presentation, diagnosis, and treatment.

Table 1
Summary of Complications of All Bariatric Procedures

Complication	Presentation	Signs & Symptoms	Diagnostic Tests	Treatment	Procedure
Anastomotic leak	1 week to 1 month	Tachycardia, dyspnea, AP,	Gastrograffin UGI or Abd CT	Resuscitate, surgical exploration	Open RYGBP, Lap RYGBP, BPD

		unexplained sepsis			
GI obstruction	1 week to 1 month	Hiccups, N/V, AP	Plain films show gastric distention with air fluid level	Nasogastric decompression	Open RYGBP, Lap RYGBP
Stomal stenosis	6 months	Postprandial AP, N/V of solids, liquids	Endoscopy or UGI contrast study	Endoscopy with dilatation	Open RYGBP, Lap RYGBP, VBG
Stomal ulcer	2 to 4 months	Epigastric or retrosternal AP, dyspepsia, N/V, UGIB	Endoscopy	Resuscitate, PPI, sucralfate	Open RYGBP, Lap RYGBP
UGIB	Early-weeks Late-1–6 months	Melena, hematemesis, hypotension, AMS	Emergent endoscopy Bleeding scan, angioplasty	Resuscitation, endoscopy, transfusion PPI	Open RYGBP, Lap RYGBP, VBG
Dumping syndrome	Immediate to 1 year	Diarrhea, abd cramps, N/V, tachycardia, flushing	Clinical	Consume small, frequent meals, Increase oral hydration	Open RYGBP, Lap RYGBP
Stomal obstruction	Months to years	N/V of solids and liquids	Endoscopy	Endoscopy, surgical revision	Open RYGBP, Lap RYGBP
GERD	Months to years	Postprandial reflux, epigastric AP, N/V	Clinical	Acid suppression, small, frequent meals	Open RYGBP, VBG
Cholelithiasis/cholecystitis	Months to years	AP with fatty foods, fever, tachycardia	Ultrasound	Cholecystectomy admission, IV antibiotics in cholecystectomy	Open RYGBP, Lap RYGBP, VBG, BPD, BPD-DS
Postcibal syndrome	Immediate to 1 year	N/V, early satiety, epigastric AP	Clinical	Consume small frequent amount	BPD, BPD-DS
Protein-energy malnutrition	Months to years	Early satiety, weakness, bone loss	Bone density studies	Supplemental vitamins	BPD, BPD-DS
Gastric slippage	Days to years	Epigastric AP, dysphagia, food intolerance, reflux	Plain film reveals large gastric bubble above band, UGI contrast study	Surgery	LAGB
Esopahgeal, gastric pouch dilatation	After band adjustment	Epigastric AP, dysphagia, reflux	UGI	Band deflation by surgeon only, close follow-up	LAGB
Band erosion	Months to years	Infected port site, no restriction to food intake	Gastrograffin UGI contrast leaks around band, endoscopy	Removal of band, repair	LAGB
Gastric injury/necrosis	24–48 h	Acute abdomen	Gastrograffin UGI	Surgery	LAGB

RYGBP = Roux-en-Y gastric bypass; Lap = laparoscopic; VBG = vertical banded gastroplasty; PPI = proton pump inhibitor; BPD = biliopancreatic diversion; BPD-DS = biliopancreatic diversion-duodenal switch; AP = abdominal pain; abd = abdominal; N/V = nausea and vomiting; UGI = upper gastrointestinal; CT = computed tomography; AMS = altered mental status; UGIB = upper gastrointestinal bleeding; abd = abdominal; LAGB = laparoscopic adjustable band gastroplasty.

Gastrointestinal (GI) obstruction

The frequency of early and late postoperative GI obstruction is higher after laparoscopic RYGBP. With the construction of the jejunojejunostomy, use of the linear stapler can result in narrowing or angulation of the afferent limb leading to early postoperative obstruction. Late bowel obstruction has been suggested as a result of surgeons leaving the mesenteric defect of the procedure open without intraoperative repair (31). Presumably, this would have the potential for an internal hernia at the open defect of the mesentery, leading to obstruction. Changes in the technique may reduce this complication.

Gastrointestinal hemorrhage

The frequency of postoperative GI hemorrhage is higher after laparoscopy than after open RYGBP, reported at 1.93% vs. 0.60%, respectively (31). The reason is felt to be bleeding from the gastric remnant, the gastrojejunostomy, or the jejunojejunostomy. The explanation for the lower bleed rate in the open method is the hand-sewn technique to create the gastrojejunostomy and oversewing of the gastric staple line. The presentation of GI hemorrhage is discussed in the open RYGBP complication section.

Stomal stenosis

Stomal stenosis is a frequent complication of laparoscopic RYGBP and is higher than the open approach. The suggested reason is use of the mechanical stapler in the laparoscopic method as compared to the hand-sewn method for open RYGBP. The frequency of stomal stenosis in the laparoscopic method is 4.73% vs. 0.67% in the open method (29 31). The symptoms are discussed in the section on open RYGBP.

Anastomotic leak

Anastomotic leak in laparoscopic RYGBP has an occurrence ranging from 2.5–6%, higher than that for the open method (11 13 15 31). However, the more experienced laparoscopic surgeons report a lower rate, approaching that of the open RYGBP group. The symptoms of anastomotic leak are the same as for the open method.

Complications of Vertical Banded Gastroplasty

Gastroesophageal reflux disease, stomal stenosis, and early gastrointestinal bleeding more commonly occur after VBG as compared to RYGBP (17 38). Staple-line disruption, pouch dilatation, incisional hernia, anemia, outlet obstruction, and Wernicke's encephalopathy occur less often.

Gastroesophageal reflux disease (GERD)

Acid reflux can be from chronic pouch overfilling by excessive food intake, from vagal nerve injury during the procedure, or from stomal stricture or delayed gastric emptying. Refer to the discussion of gastroesophageal reflux disease in the open RYGBP complication section.

Stomal stenosis

Stomal stenosis is quite common with a higher incidence in VBG that is supported by Marlex mesh or silastic ring gastroplasty due to peristomal scarring (38). Strictures may also occur within 6 months at the gastrojejunal anastomosis. Patients present with postprandial epigastric pain and vomiting of undigested food and eventually liquids. Endoscopy should be used for the diagnosis and measurement of the stoma diameter. Endoscopy also provides the therapeutic intervention of dilatation at the stoma site using a balloon or over-the-wire bougie.

Gastrointestinal bleeding

Gastrointestinal bleeding occurs more commonly in the early postoperative period after VBG and is most often from the staple line. Early GI bleeding may be diagnosed by endoscopy and presentation and treatment are discussed in the section on open RYGBP.

Complications of Biliopancreatic Diversion with or without Duodenal Switch

This procedure reports a risk of stomal ulcer and a "postcibal" syndrome that is similar to the dumping syndrome of RYGBP. The duodenal switch reduces the risk of both of these complications. The main complications of this surgery are the long-term nutritional complications, including protein-calorie malnutrition, cholelithiasis and cholecystitis, deficiencies of calcium, thiamine, and fat-soluble vitamins, and diarrhea (9). Diarrhea, flatulence, and foul-smelling stools are commonly reported due to the malabsorption of starch and fat.

Postcibal syndrome

This surgery usually creates a "postcibal" syndrome for the first year postoperatively. The symptoms are early satiety with vomiting and epigastric pain from rapid distention of the ileum by oral intake. It usually resolves after 1 year and is not technically a dumping syndrome (9). There is no treatment, and patients should ingest small amounts more frequently to avoid dehydration.

Cholelithiasis

Cholelithiasis and cholecystitis present with the highest frequency in this bariatric surgery owing to increased bile sludging. Selective prophylactic cholecystectomy is often performed during the procedure due to this higher incidence.

Protein-energy malnutrition

In protein-energy malnutrition, patients develop nitrogen and insulin deficits that lead to lipolysis and proteolysis of skeletal muscle to supply needed amino acids to preserve visceral muscle (9). Patients with the combination of the postcibal syndrome of early satiety and vomiting along with inadequate food intake are at highest risk for developing protein-energy malnutrition. These effects are all long-term nutritional deficiencies that result in bone demineralization requiring supplementation. As long as adequate supplementation of protein, fat-soluble vitamins, calcium and thiamine occurs, the patient will prevent bone loss and metabolic impairment from malnutrition.

Complications of Laparoscopic Adjustable Band Gastroplasty (LAGB)

The LAGB, or Lap-Band® (Allergan, Inc., Irvine, CA), is currently the only Food and Drug Administration-approved adjustable band procedure in the United States. Outside of the United States, the LAGB is the most commonly performed bariatric surgery (39). This procedure has a lower mortality rate as compared with the RYGBP (0.05% vs. 0.3%, respectively), and is adjustable and entirely reversible (40). The initial experience in the United States seemed to show inferior results with high complication rates as compared with other countries (41). More recently, better results have been reported by utilizing modifications in the technique with closer follow-up for band adjustments (42). For this reason, the Lap-Band procedure is gaining in popularity in this country. However, the Lap-Band is associated with several unique complications, which the emergency physician may encounter.

Gastric slippage

Gastric slippage remains the most common complication even though technical modifications have decreased its incidence (43 44). This occurs when a portion of the stomach becomes prolapsed relative to the band, creating an overly large upper gastric pouch. This enlarged gastric pouch serves as a reservoir for food and gastric secretions, disrupting the normal mechanical passage of ingested contents through the band. This can occur as a chronic process; however, acute onset of severe vomiting can precipitate gastric slippage. Patients presenting with this complication develop epigastric pain, dysphagia, food intolerance, vomiting, and reflux. A plain upright radiograph of the abdomen may show a large gastric air bubble with an air fluid level above the band. An upper GI contrast study will clearly show the slippage and its location. If there is simply mild gastric pouch dilatation, the surgeon may be able to deflate the band and allow the stomach to return to normal. However, a true gastric slippage generally requires surgery to fix, which can often be performed laparoscopically. Initial management in the ED includes fluid resuscitation, correction of electrolyte disturbances, and notification of the managing surgeon. Repair within a 24-h period of time is permissible in the clinically well patient who responds to resuscitation. It is not recommended that the emergency physician attempt to deflate the band, even if prompted by the surgeon. The port and tubing of the system can be permanently damaged if not accessed appropriately.

Gastric stoma obstruction

Obstruction of food from the pouch through the band to the rest of the stomach can occur, particularly if the band is too tight. This can present as either an early or late complication. Patients with early obstruction will have difficulty tolerating a liquid diet or perhaps even their own saliva. A postoperative contrast study will usually show the degree of obstruction. If a complete obstruction is present, surgery is usually necessary to reposition the band. Partial obstruction may occur due to acute swelling or hematoma around the region of the band at the time of surgery. If the obstruction is partial, conservative management may be effective. Patients may improve with hydration and close observation in an inpatient setting. After a period of time the postoperative edema or hematoma usually resolves, allowing the patient to begin a liquid diet.

Late stoma obstruction may occur after a tightening adjustment of the band, in which case the treatment is simply to deflate the band. Late obstructions can also result from gastric dilation or slippage, which is managed accordingly.

Esophageal and gastric pouch dilatation

Esophageal and gastric pouch dilatation will result usually from a band that is too tight, leading to obstruction. Also, patients who are not compliant with their diet can stretch the gastric pouch from inappropriate food intake. The symptoms are similar to those seen with gastric slippage. In general, these changes are reversible if addressed promptly. Diagnosis is established with an upper GI contrast study. Gastric pouch dilatation is essentially a precursor to gastric slippage and can be relieved by deflating the band completely. After a period of time the stomach pouch resumes its normal size, at which point the band can be carefully adjusted again. Esophageal dilatation can be a serious consequence which, if left untreated, can result in irreversible damage, such as esophageal dysmotility. This also occurs from a band that is either too tight or improperly placed, and may be seen alongside gastric pouch dilatation. The management is similar with complete deflation of the band. Close follow-up of these patients is mandatory, and band removal is necessary if problems persist.

Band erosion

Erosion of the band into the stomach resulted in approximately 1% of patients in the Food and Drug Administration clinical trial (45). Usually, band erosion is a chronic process during which a portion of the band gradually encroaches against and eventually into the lumen of the stomach. Oftentimes a fibrous capsule will develop around the band, preventing free soilage of gastric contents into the peritoneal cavity. Therefore, band erosion may present in a more benign way than would be expected. In some cases the initial presentation of an erosion is an infection at the access port site. For this reason, band erosion must be ruled out any time a port site infection occurs. Some patients will present only with a non-functioning band, with no restriction of food through the stomach. An upper GI study will show contrast media surrounding the band as the contrast is able to leak around the eroded portion of the band. The best way to diagnose band erosion is with endoscopy, during which a portion of the band is usually well visualized from inside the stomach. Treatment requires removal of the band and repair of the stomach.

Gastric injury and necrosis

Acute gastric injury is a possible complication during implantation of the band. If unrecognized, peritonitis will result and re-operation is required with removal of the band and repair of the stomach. These patients will usually present within the first 24–48 h with the expected signs of an acute abdomen from a perforated viscus. Emergency management includes fluid resuscitation, broad spectrum antibiotics, and immediate notification of the surgeon.

A rarely reported late-term complication seen in the Lap-Band experience is gastric necrosis. This is believed to be due to ischemia of the stomach wall from a combination of gastric prolapse and pressure from the band itself. The patient will appear toxic with an acute abdomen. Such a presentation with evidence of an overly distended gastric pouch on contrasted upper GI or CT scan should alert the clinician of possible gastric necrosis. The surgeon should be immediately notified because emergent surgery is the required treatment.

Summary

Emergency physician should attempt to integrate the complications of bariatric surgery into their clinical practice because they will be seeing more postoperative patients. The best approach is to arm oneself with knowledge of the anatomical operative changes as well as an understanding of complications specific to the bariatric procedure practiced at your institution.

References

1. Flegal K.M., Carroll M.D., Luczmarsski R.J., et. al.: Overweight and obesity in the United States: prevalence and trends, 1960–1994. Int J Obes 1998; 22: pp. 39-47.
View In Article Cross Ref (http://dx.doi.org.ezproxy.surgeons.org/10.1038/sj.ijo.0800541)

2. Omalu B.I., Luckasevic T., Shakir A.M., Rozin L., Wecht C.H., Kuller L.H.: Postbariatric surgery deaths, which fall under the jurisdiction of the coroner. Am J Forensic Med Pathol 2004; 25: pp. 237-242.
View In Article Cross Ref (http://dx.doi.org.ezproxy.surgeons.org/10.1097/01.paf.0000136638.26060.78)

3. Mokdad A.H., Bowman B.A., Ford E.S., et. al.: The continuing epidemics of obesity and diabetes in the United States. JAMA 2001; 286: pp. 1195-1200.
View In Article Cross Ref (http://dx.doi.org.ezproxy.surgeons.org/10.1001/jama.286.10.1195)

4. Mitka M.: Surgery for obesity: demand soars amid scientific, ethical questions. JAMA 2003; 289: pp. 1761-1762.
View In Article Cross Ref (http://dx.doi.org.ezproxy.surgeons.org/10.1001/jama.289.14.1761)

5. World Health Organization Regional Office for the Western Pacific, Manila, Philippines. Workshop on obesity prevention and control strategies in the Pacific. WHO report RS/2000/GE/23 (SMA); July 2002.
View In Article

6. North American Association for the Study of Obesity and the National Heart, Lung, and Blood Institute: The practical guide: identification, evaluation, and treatment of overweight and obesity in adults. (Publication 00-4084)2000.National Institutes of HealthBethesda, MD
View In Article

7. Gastrointestinal surgery for severe obesity: National Institutes of Health Consensus Development Conference Statement. Am J Clin Nutr 1992; 55: pp. 615S-619S.
View In Article Cross Ref (http://dx.doi.org.ezproxy.surgeons.org/10.1093/ajcn/55.2.615s)

8. Jones K.: Bariatric surgery—where do we go from here?. Int Surg 2004; 89: pp. 51-57.
View In Article Cross Ref (http://dx.doi.org.ezproxy.surgeons.org/10.1016/j.bbmt.2003.12.254)

9. Schirmer B.D.: Morbid obesity.Townsend C.M.Beauchamp R.D.Evers B.M.Mattox K.L.Sabiston textbook of surgery.2004.SaundersPhiladelphia:pp. 384-390.
View In Article

10. Deitel M., Shikora S.A.: The development of the surgical treatment of morbid obesity. J Am Coll Nutr 2002; 21: pp. 365-371.
View In Article Cross Ref (http://dx.doi.org.ezproxy.surgeons.org/10.1080/07315724.2002.10719237)

11. Wittgrove A.C., Clark G.W.: Laparoscopic gastric bypass, Roux-en-Y-500 patients: technique and results, with 3–60 month follow-up. Obes Surg 2000; 10: pp. 509-513.
View In Article Cross Ref (http://dx.doi.org.ezproxy.surgeons.org/10.1381/096089200321593706)

12. DeMaria E., Sugerman H., Kellum J., Meador J., Wolfe L.G.: Results of 281 consecutive total laparoscopic Roux-en-Y gastric bypasses to treat morbid obesity. Ann Surg 2002; 235: pp. 640-647.
View In Article Cross Ref (http://dx.doi.org.ezproxy.surgeons.org/10.1097/00000658-200205000-00005)

13. Nguyen N.T., Hunh S.H., Palmer L.S., Wolfe B.M.: A comparison study of laparoscopic versus open gastric bypass for morbid obesity. J Am Coll Surg 2000; 191: pp. 149-155.
View In Article

14. Westling A., Bjurling K., Ohrvall M., Gustavsson S.: Silicone-adjustable gastric banding: disappointing results. Obes Surg 1998; 8: pp. 467-474.
View In Article Cross Ref (http://dx.doi.org.ezproxy.surgeons.org/10.1381/096089298765554386)

15. Higa K.D., Ho T., Boone K.B.: Laparoscopic Roux-en-Y gastric bypass: technique and 3-year follow-up. J Laparoendosc Adv Surg Tech A 2001; 11: pp. 377-382.
View In Article Cross Ref (http://dx.doi.org.ezproxy.surgeons.org/10.1089/10926420152761905)

16. Jones K.B.: The effect of gastric bypass on cholesterol, HDL, and the risk of coronary heart disease. Obes Surg 1992; 2: pp. 83-85.
View In Article Cross Ref (http://dx.doi.org.ezproxy.surgeons.org/10.1381/096089292765560600)

17. del Amo D.A., Diez M.M., Guedea M.E., Diago V.A.: Vertical banded gastroplasty: is it a durable operation for morbid obesity?. Obes Surg 2004; 14: pp. 536-538.
View In Article Cross Ref (http://dx.doi.org.ezproxy.surgeons.org/10.1381/096089204323013578)

18. Lee W.J., Huang M.T., Yu P.J., Wang W., Chen T.C.: Laparoscopic vertical banded gastroplasty and laparoscopic gastric bypass: a comparison. Obes Surg 2004; 14: pp. 626-634.

View In Article Cross Ref (http://dx.doi.org.ezproxy.surgeons.org/10.1381/096089204323093390)

19. Scopinaro N., Marihari G.M., Cancerini G.: Laparoscopic standard biliopancreatic diversion, technique and preliminary results. Obes Surg 2002; 12: pp. 241-244.
View In Article Cross Ref (http://dx.doi.org.ezproxy.surgeons.org/10.1381/096089202762552692)

20. Hess D.S., Hess D.W.: Biliopancreatic diversion with a duodenal switch. Obes Surg 1998; 8: pp. 267-282.
View In Article Cross Ref (http://dx.doi.org.ezproxy.surgeons.org/10.1381/096089298765554476)

21. Anthone G., Lord R., DeMeesler T., Crooks P.F.: The duodenal switch operation for treatment of morbid obesity. Ann Surg 2003; 238: pp. 618-628.
View In Article Cross Ref (http://dx.doi.org.ezproxy.surgeons.org/10.1097/01.sla.0000090941.61296.8f)

22. O'Brien P.E., Dixon J.B.: Weight loss and early and late complications—the international experience. Am J Surg 2002; 184: pp. 42S-45S.
View In Article

23. Belachew M., Belva P.H., Desaive C.: Long term results of laparoscopic adjustable gastric band for the treatment of morbid obesity. Obes Surg 2002; 12: pp. 564-568.
View In Article Cross Ref (http://dx.doi.org.ezproxy.surgeons.org/10.1381/096089202762252352)

24. Dargent J.: Laparoscopic adjustable gastric banding: lessons from the first 500 patients in a single institution. Obes Surg 1999; 9: pp. 446-452.
View In Article Cross Ref (http://dx.doi.org.ezproxy.surgeons.org/10.1381/096089299765552729)

25. Vertruyen M.: Experience with Lap-Band system up to 7 years. Obes Surg 2002; 12: pp. 569-572.
View In Article Cross Ref (http://dx.doi.org.ezproxy.surgeons.org/10.1381/096089202762252361)

26. Favretti F., Cadiere G.B., Segato G., et. al.: Laparoscopic banding: selection and technique in 830 patients. Obes Surg 2002; 12: pp. 385-390.
View In Article Cross Ref (http://dx.doi.org.ezproxy.surgeons.org/10.1381/096089202321087922)

27. Fernandez A., DeMaria E.J., Tichansky D.S., et. al.: Multivariate analysis of risk factors for death following gastric bypass for treatment of morbid obesity. Ann Surg 2004; 239: pp. 698-703.
View In Article Cross Ref (http://dx.doi.org.ezproxy.surgeons.org/10.1097/01.sla.0000124295.41578.ab)

28. See C., Carter P.L., Elliott D., et. al.: An institutional experience with laparoscopic gastric bypass complications seen in the first year compared with open gastric bypass complications during the same period. Am J Surg 2002; 183: pp. 533-538.
View In Article

29. Nguyen N.T., Ho H.S., Palmer L.S., Wolfe B.M.: A comparison study of laparoscopic versus open gastric bypass for morbid obesity. Surg Endosc 2002; 16: pp. 1653-1657.
View In Article Cross Ref (http://dx.doi.org.ezproxy.surgeons.org/10.1007/s00464-002-8531-5)

30. Ukleja A., Stone R.L.: Medical and gastroenterologic management of the post-bariatric surgery patient. J Clin Gastroenterol 2004; 38: pp. 312-321.
View In Article Cross Ref (http://dx.doi.org.ezproxy.surgeons.org/10.1097/00004836-200404000-00004)

31. Podnos Y.D., Jimenez J.C., Wilson S.E., Stevens M., Nguyen N.T.: Complications after laparsocopic gastric bypass: a review of 3464 cases. Arch Surg 2003; 138: pp. 957-961.
View In Article Cross Ref (http://dx.doi.org.ezproxy.surgeons.org/10.1001/archsurg.138.9.957)

32. Rajdeo H., Bhuta K., Ackerman N.B.: Endoscopic management of gastric outlet obstruction following surgery for morbid obesity. Am Surg 1989; 55: pp. 724-727.
View In Article

33. Hocking M.P., Bennett R.S., Rout W.R., et. al.: Pouch outlet obstruction following vertical ring gastroplasty for morbid obesity. Am J Surg 1990; 160: pp. 496-500.
View In Article

34. Shiffman M.L., Sugerman H.J., Kellum J.M., et. al.: Gallstone formation after rapid weight loss: a prospective study in patients undergoing gastric bypass surgery for treatment of morbid obesity. Am J Gastroenterol 1991; 86: pp. 1000-1005.
View In Article

35. Bridges K.R., Bunn H.F.: Anemias with disturbed iron metabolism.Isselbacher K.J.Braunwald E.Wilson J.D.Harrison's principles of internal medicine.1994.McGraw-HillNew York:pp. 1723-1724.
View In Article

36. Victor M., Martin J.B.: Nutritional and metabolic diseases of the nervous system.Isselbacher K.J.Braunwald E.Wilson J.D.Harrison's

principles of internal medicine.1994.McGraw-HillNew York:pp. 2329-2331.
View In Article

37. Babior B.M., Bunn H.F.: Megaloblastic anemias.Isselbacher K.J.Braunwald E.Wilson J.D.Harrison's principles of internal medicine.1994.McGraw-HillNew York:pp. 1729-1730.
View In Article

38. MacLean L.D., Rhode B.M., Forse R.A.: Late results of vertical banded gastroplasty for morbid and super obesity. Surgery 1990; 107: pp. 20-27.
View In Article

39. Fisher B.L., Schauer P.: Medical and surgical options in the treatment of severe obesity. Am J Surg 2002; 184: pp. 9S-16S.
View In Article

40. Chaman A., Kiroff G., Game P., et. al.: Systematic review of laparoscopic adjustable gastric banding in the treatment of obesity. (ASERNIP-S Report No. 31)2002.Australian Safety and Efficacy Register of New Interventional Procedures-SurgicalAdelaide, South Australia:pp. 18.
View In Article

41. DeMaria E.J., Sugerman H.J., Meador J.G., et. al.: High failure rate after laparoscopic adjustable silicone gastric banding for treatment of morbid obesity. Ann Surg 2001; 233: pp. 809-818.
View In Article Cross Ref (http://dx.doi.org.ezproxy.surgeons.org/10.1097/00000658-200106000-00011)

42. Ren C.J., Horgan S., Ponce J.: US experience with the LAP-BAND system. Am J Surg 2002; 184: pp. 46S-50S.
View In Article

43. Spivak H., Favretti F.: Avoiding postoperative complications with the Lap-Band system. Am J Surg 2002; 184: pp. 31S-37S.
View In Article

44. Belachew M.B., Zimmermann J.M.: Evolution of a paradigm for laparoscopic adjustable gastric banding. Am J Surg 2002; 184: pp. 21S-25S.
View In Article

45. U.S. Food and Drug Administration, Center for Devices and Radiological Health. LAP-BAND Adjustable Gastric Banding (LAGB) System-P0000008; Aug 2002.
View In Article

ELSEVIER Copyright © 2021 Elsevier, Inc. All rights reserved.

RELX Group™